

Long QT Syndrome Manifesting As Pulseless Epilepsy

Fuad Abed Abass, Madhukar Shahi¹, Nirmal Kumar, Moneesha Bhargava, Sangita Gupta and Jacob M. Puliyel

Department of Pediatrics and ¹Cardiology, St. Stephen's Hospital, Delhi, India

Abstract. A-10-year-old child admitted with repeated seizures due to the long QT syndrome is described. The cardiac origin of the epilepsy was suggested by the fact that during the episode of convulsions his peripheral pulses were not palpable. [Indian J Pediatr 2003; 70 (1) : 97-100]

Key words : Long QT syndrome; Epilepsy; Peripheral pulses

Long QT syndrome (LQTS) may masquerade as epilepsy.¹⁻⁵ The underlying cardiac abnormality is suspected on account of a family history of deafness or unexplained sudden death.⁴ However, it is unusual to find electroencephalographic (EEG) changes in LQTS. To our knowledge there are only 7 cases of LQTS with EEG changes reported in English literature (Table 1). The correct diagnosis under these circumstances is very difficult to make. We report here a case diagnosed by chance, on account of a pediatrician noting the absence of peripheral pulses during the seizure episode.

CASE REPORT

A-10-year-old boy who had a 2-year history of episodes of generalized tonic clonic seizures (GTCS) occurring once every month, reported to us for a sudden increase in the frequency of seizures. He had had 5 GTCS in the week prior to admission. These GTCS were brief, not preceded by an aura and not associated with loss of sphincter control or postictal symptoms. These were not related to physical exercise or emotional stress. There was no family history of seizures, sudden cardiac death, deafness or syncope. The child had a GTCS half an hour prior to admission. Upon arrival in the emergency department, with the presumptive diagnosis of epilepsy, intravenous phenytoin in a loading dose of 20 mg per kg was infused slowly. He had three further GTCS in the span of four hours after admission and was treated with diazepam. Each seizure followed a typical pattern, it started as a sudden loss of consciousness with tonic spasm of the whole body for about 20 seconds, followed by clonic contractions of the four limbs lasting for 30-40 seconds. After the episode he was disoriented for a couple of minutes. None of these episodes were associated with

involuntary urination or defecation nor were these preceded by an aura. When he was having his third convulsion in the ward, it was noticed that his arterial pulses were not palpable despite the presence of clearly audible heart sounds.

An ECG was done after the episode but no arrhythmia was noticed (Fig. 1). Half an hour later the child had another convulsion and so magnetic resonance imaging was done to look for an intra-cranial lesion, which could have caused the seizure. This scan revealed bilateral symmetrical hyperintensity in cortical and putaminal regions with oedematous gyral pattern on diffusion weighted and flare sequences suggesting diffuse hypoxia (Fig. 2).




Fig. 1. ECG shows sinus rhythm at a rate of 78 bpm
QT interval is markedly prolonged
QT = 0.52 sec, RR = 0.76 sec
QTc = 0.59 sec




Fig. 2. ECG showing wide complex polymorphic tachycardia, the changing polarity of the complexes suggests 'torsades de pointes'

At the end of the procedure the child manifested his 5th GTCS episode after admission. An ECG was done concurrent to the seizure activity and it revealed the presence of polymorphic ventricular tachycardia [VT] (Fig. 3). Reevaluation of the previous ECG showed long QT interval, which was not noted earlier. The child was administered 500 mg of intravenous magnesium sulphate

Reprint requests : Dr. Jacob M. Puliyel, Department of Pediatrics and Neonatology, St. Stephen's Hospital, Tis Hazari, Delhi 110054, India
Fax : 0091 11 3932412. E-mail: Puliyel@vsnl.com

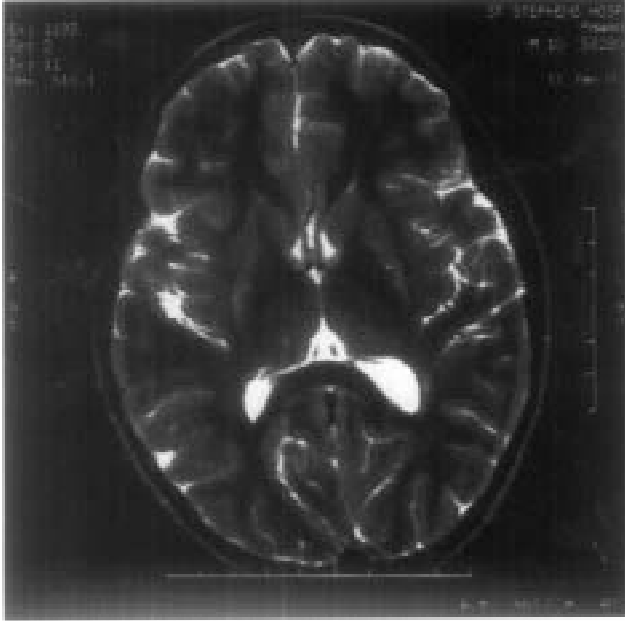


Fig. 3. MRI coronal flair sequence demonstrating bilateral hyperintensities and gyral edema.

and this was repeated after 5 minutes. However, he continued to have runs of polymorphic VT. Temporary transvenous pacing was therefore instituted at a rate of 100 bpm and this completely suppressed the VT. Esmolol was started concurrently as a bolus infusion of 100 ug/kg/min over 4 minutes, and then increasing by 50ug/kg/min until a dose of 300ug/kg/min was achieved. The child remained asymptomatic subsequently. Pacing was discontinued after 96 hours and oral metoprolol was

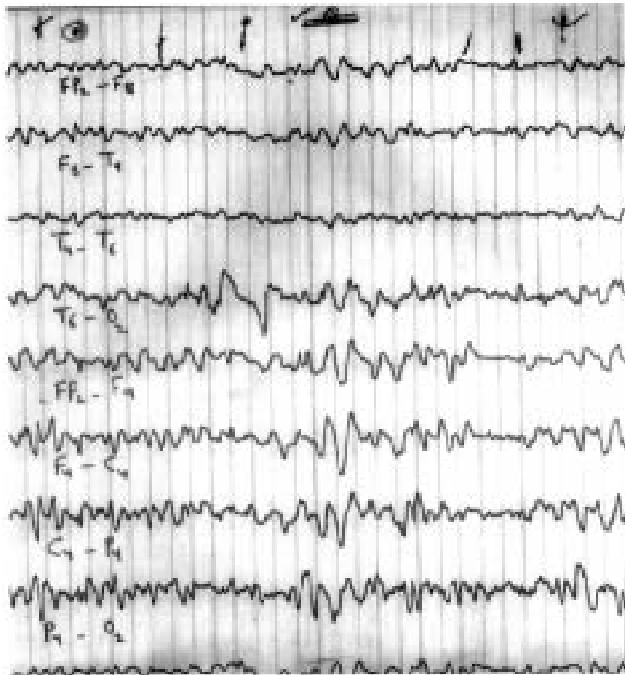

Fig. 4. Post hyperventilation EEG showing high amplitude slow waves.

administered at a dose of 25 mg four times daily. He had no further seizures. His ECG continued to show a prolonged QTc. An EEG done 7 days later revealed well-modulated alpha activity with posterior dominance. A single sharp slow wave was seen after photic stimulation and high amplitude slow waves were also seen after hyperventilation (Fig. 4).

The child was discharged following 10 days of hospitalization. He was advised to continue metoprolol therapy. No anticonvulsant drugs were prescribed. He had no further convulsions.

DISCUSSION

The Long QT syndrome may be acquired due to the use of drugs like cisapride and macrolide antibiotics, electrolyte abnormalities such as hypokalemia and hypocalcemia, subarachnoid haemorrhage or cardiac disease such as myocarditis. A more exhaustive list is presented by Salen *et al*.⁹ The congenital form of LQTS can be either hereditary or nonhereditary sporadic form. The hereditary varieties are the autosomal recessive Jervell and Lange Nielsen syndrome and Romano Ward syndrome which may be autosomal recessive or dominant. Our patient had no family history suggestive of LQTS and ECG screening of the immediate family members did not detect any abnormality. He therefore belongs to the nonhereditary sporadic group.

The association of cardiac rhythm abnormality with seizures may be due to the interplay of a variety of factors. Ventricular tachycardia and Stokes Adam's attacks may be associated with urinary incontinence, tonic clonic movements and temporary disorientation after the event and this may mimic seizure activity.¹⁰ Seizures can themselves cause premature atrial or ventricular complexes, ST segment and T wave changes, conduction block, ventricular tachycardia and prolonged bradycardia.¹¹ Drugs such as phenytoin given during a seizure can cause ventricular arrhythmias if infused rapidly.¹² Finally recurrent episodes of ventricular tachy-brady arrhythmia producing poor cerebral perfusion can cause hypoxic injury to the brain and thus precipitate seizure activity.³ The MR scan in our patient suggests that hypoxic injury to the brain may be the cause of his convulsions. An EEG done 7 days after the last ictus showed abnormalities suggesting the diagnosis of epilepsy. Our patient's symptoms did not respond to anticonvulsants but were readily controlled after cardiac pacing and β blocker administration. He was discharged without antiepileptic treatment.

The diagnosis of LQTS rests on the calculation of a corrected QT interval (QTc) of more than 460-480 milliseconds using Bazetts Formula ($QTc = QT / \sqrt{RR}$).¹³ This corrected QT is not calculated routinely on an ECG and the diagnosis of LQTS is often missed initially¹⁴ as happened in our patient. Some patients with LQTS

Long QT Syndrome Manifesting as Pulseless Epilepsy

Table 1. Cases of Long QT Syndrome Presenting As Epilepsy with EEG Changes

Pt. No.	Author (year)	Sex	Age of onset of seizure	Seizure type	Frequency	Family H/o Sudden Seizure Death	Initial Diagnosis	Time to reach correct diagnosis	Initial E.E.G.	Subsequent E.E.G.	CT/MRI	Treatment outcome and
1.	Desilvey ⁶ (1980)	F	8 Yrs	Grand Mal	Infrequent	+	Grand mal epilepsy	23 years	NA	Slow waves and abortive	Not done	Primidone—improved
2.	Gospe ⁷ (1989)	M	8 Yrs	Fainting	1/year	-	Epilepsy	4½ years	Bursts of generalized spike and polyspike and slow wave complexes during photic stimulation at 14 Hz.	NA	Not done	Nadolol improved
3.	Gospe ⁸ (1990)	M	11Yrs	Partial Motor	2 episodes in one day	One additional family member has been diagnosed	Seizure disorder	2 days	High voltage slow waves in left temporal region	NA	Not done	Atenolol improved
4.	Pfammter et al ⁵ (1995)	M	5 Yrs	Drop attacks with tonic clonic seizures	4-10/year	NA	CTCS	5 years	Normal background activity, repetitive centro-parietal slow waves during sleep	Normal in the awake state	Not done	β blocker improved
5.	Pfammter et al ⁵ (1995)	F	9 Yrs	Drop attacks with tonic clonic seizures	Weekly	NA	GTCS	1 year	Abnormally slow background activity, repetitive generalized spike wave complexes.	Same changes	Not done	β blocker improved
6.	Pfammter et al ⁵ (1995)	M	7 Yrs	Drop attacks	2/year	NA	Atonic seizure	Diagnosed postmortem	Abnormally slow background activity repetitive right temporal sharp waves	Same changes	Not done	Experiences improved
7.	Pfammter et al ⁵ (1995)	M	5 Yrs	Drop attacks	1/year	NA	Atonic seizure	1 week	Normal background activity, generalized spike waves during drowsiness	Normal in the awake state	Not done	β blocker improved

NA : Not Available, GTCS : Generalized Tonic Clonic Seizure, CT : Computerised Tomography, MRI : Magnetic Resonance Imaging

intermittently have normal QTc interval² and 1% of the normal population may have a long QT interval of more than 460 millisecond.¹⁵ Diagnosis is therefore not easy. Diagnostic criteria have been proposed in 1985¹⁶ and then later modified by Schwartz *et al* in 1993.¹⁷

Congenital LQTS has been attributed to mutations in the genes encoding for cardiac ion channels. To date, eight genes have been mapped. All of them are associated with the syndromic type of LQTS, there is hope that this may open a new window of specific gene therapy which may be applicable in the near future.¹⁸

Currently the standard therapeutic approach in LQTS is the initiation of β blockers at the time of diagnosis. When medical therapy fails, left cervical sympathetic denervation (LCSD), pacemaker implantation or the implantation of an automatic cardioverter defibrillator (AICD) are resorted to.¹⁸

We have reported a child with non-familial LQTS who presented with seizures. The absence of a peripheral pulse during the episode of generalized tonic-clonic seizures was the clue to the cardiac origin of these symptoms. MRI scan showed evidence of hypoxic changes and EEG taken one week later was abnormal. His seizures responded dramatically to cardiac pacing and β blocker therapy. Other authors have suggested getting an ECG done in all cases of afebrile seizures of recent onset, to diagnose or exclude the LQTS.^{2,3} Still others have disputed this as being impractical.⁵ Our case shows that a careful examination of the pulse during a seizure may aid in the diagnosis of the LQTS due to associated ventricular fibrillation or polymorphic ventricular tachycardia and suggest need for ordering an ECG and cardiac monitoring.

REFERENCES

- Bell MR, Kozak RJ. Seizures and the long QT syndrome. *Ann Emerg Medicine* 1996; 28 : 556-560.
- Salen P, Nadkarni V. Congenital long QT syndrome: A case report illustrating diagnostic pitfalls. *J Emerg Medicine* 1999; 17: 859-864.
- Davis Am, Wilkinson JL. The long QT syndrome and seizures in childhood. *J Pediatric Child Health* 1998; 34: 410-411.
- Pacia SV, Devinsky O, Luciano DJ, Vazquez B. The prolonged QT syndrome presenting as epilepsy: a report of two cases and literature review. *Neurology* 1994; 44 : 1408-1410.
- Pfammatter JP, Donati F, Durig P, Weber Jw, Stocker FP, Vassella F. Cardiac arrhythmias mimicking primary neurological disorders: a difficult diagnostic situation. *Acta Paediatr* 1995; 84 : 569-572.
- Desilvey DL, Moss AJ. Primidone in the treatment of long QT syndrome: QT shortening and ventricular arrhythmia suppression. *Ann of Intern Med* 1980; 93 : 53-54.
- Gospe SM, Choy M. Hereditary long QT syndrome presenting as epilepsy: Electroencephalography laboratory diagnosis. *Ann Neurol* 1989; 25 : 514-516.
- Gospe SM, Gabor AJ. Electroencephalography Laboratory diagnosis of prolonged QT interval. *Ann Neurol* 1990; 28 : 387-390.
- Liberthson R. Sudden death from cardiac causes in children and young adults. *N Engl J Med* 1996; 334 : 1039-1044.
- Gorlin RJ. Genetic hearing loss associated with miscellaneous disorders. In: Gorlin RJ, Toriello HV, Cohen MM. *Hereditary Hearing Loss and Its Syndromes*. 1st edn, New York; Oxford University Press, 1995; 418-419.
- Hirsch CS, Martin DL. Unexpected death in young epileptics. *Neurology*. 1971; 21: 682-690.
- Praffit K. Antiepileptic drugs. In *Martindale*, 32 edition, Pharmaceutical Press; London 1999; 352-358.
- Bazett HC. An analysis of the time relationship of electrocardiograms. *Heart* 1920; 7 : 353-370.
- Moss AJ, Schwartz PJ, Crampton RS, Tzivoni D, Locati EH *et al*. The long QT syndrome: Prospective longitudinal study of 328 families. *Circulation* 1991; 84 : 1136-1144.
- Guntheroth WG. Long QT syndrome in children. *Circulation* 1993; 87 : 2058-2059.
- Schwartz PJ. Idiopathic long QT syndrome: progress and questions. *Am Heart J* 1985; 2 : 399-411.
- Schwartz PJ, Moss AJ, Vincent GM *et al*. Diagnostic criteria for the long QT syndrome. *Circulation* 1993; 88 : 782-784.
- Li H, Garcia JF, Towbin JA. Current concepts in long QT syndrome. *Pediatr Cardiology* 2000; 21: 542-550.